

Regiones de la mano

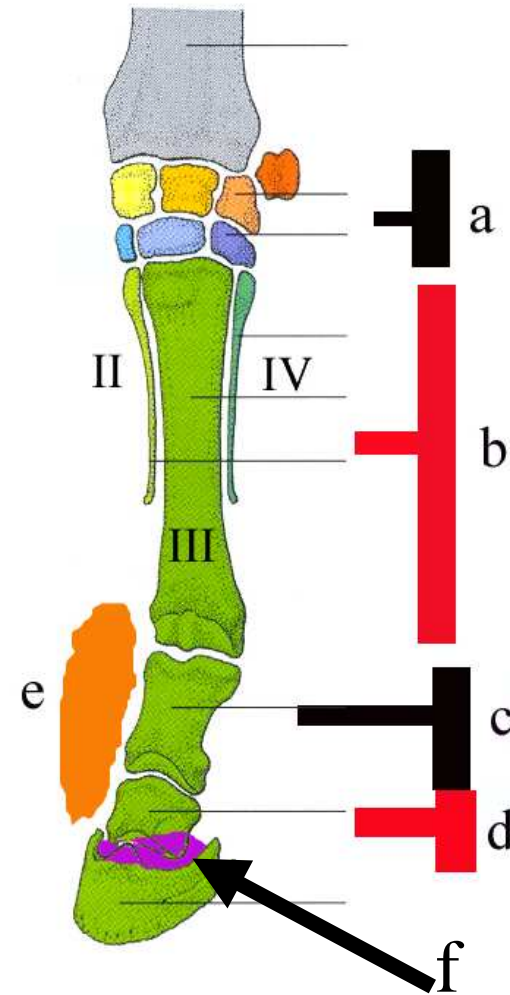
Dr Guillermo Graziotti

Regiones de la mano

regiones

a carpo, b metacarpo, falange proximal, d falange media, e compedal, f coronal

Regiones de la mano

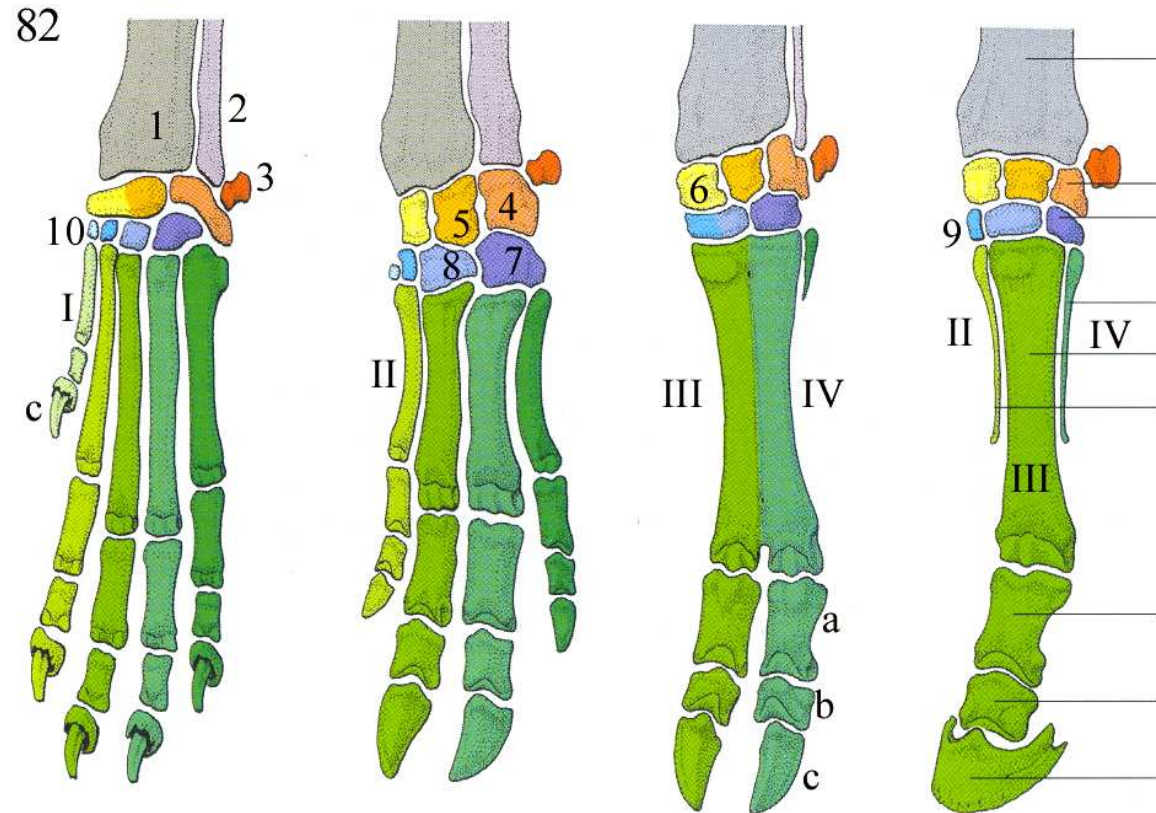


Esqueleto de la mano

1 radio, 2 ulna, 3
carpoaccesorio, 4
carpoulnar, 5
carpintermedio 6
carporradial, 7 IV
carpiano, 8 III
carpiano, 9 II
carpiano, 10 I
carpiano

En números romanos
huesos del
metacarpo, a b y c
falanges proximal
medial y distal.

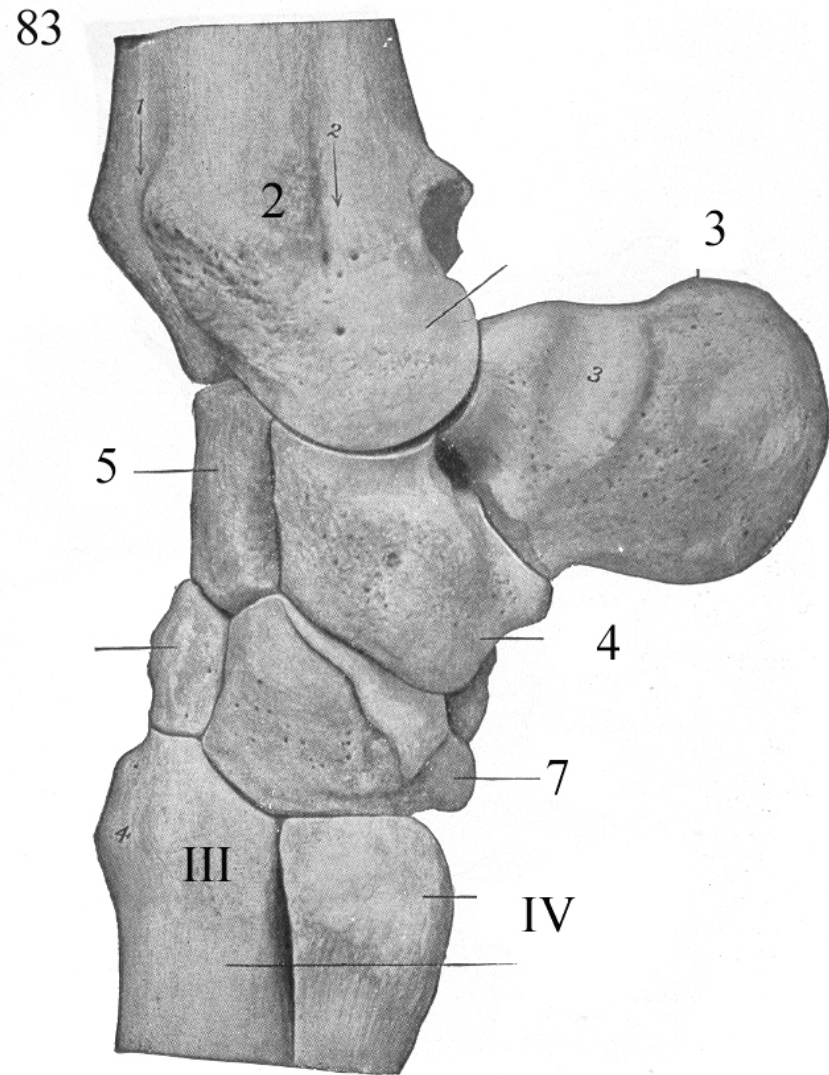
No están indicados los
huesos sesamoideos



Huesos del carpo

Ver referencias
en imagen
previa

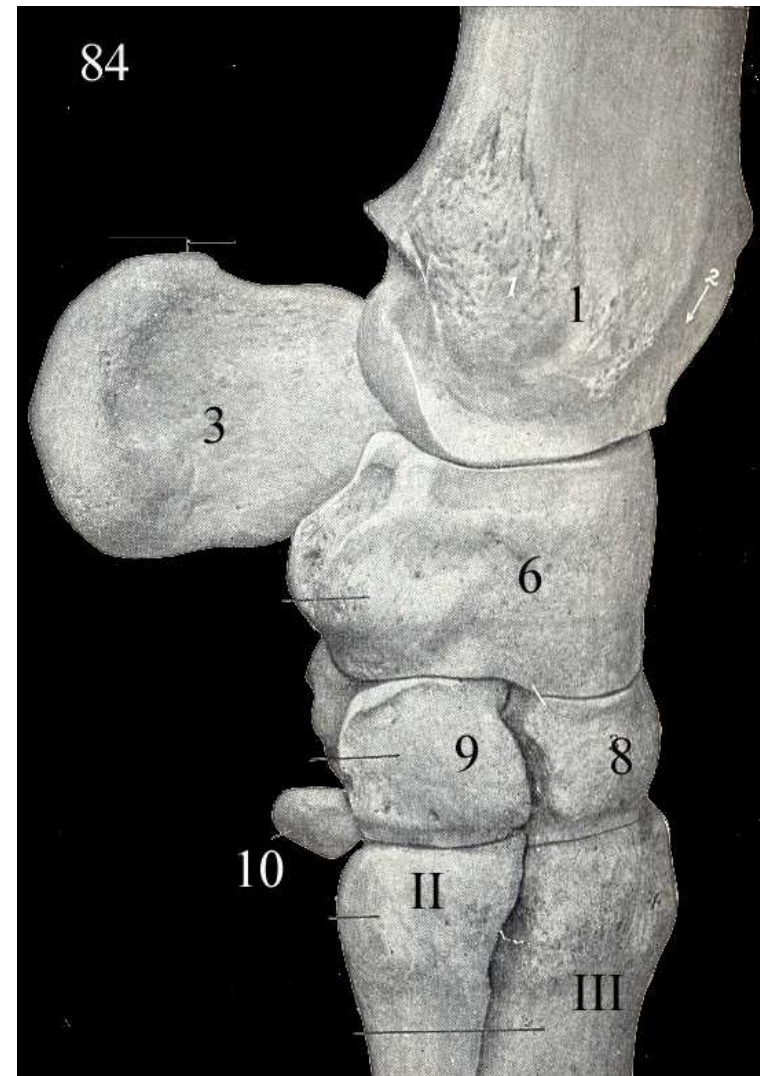
Vista lateral



Huesos del carpo

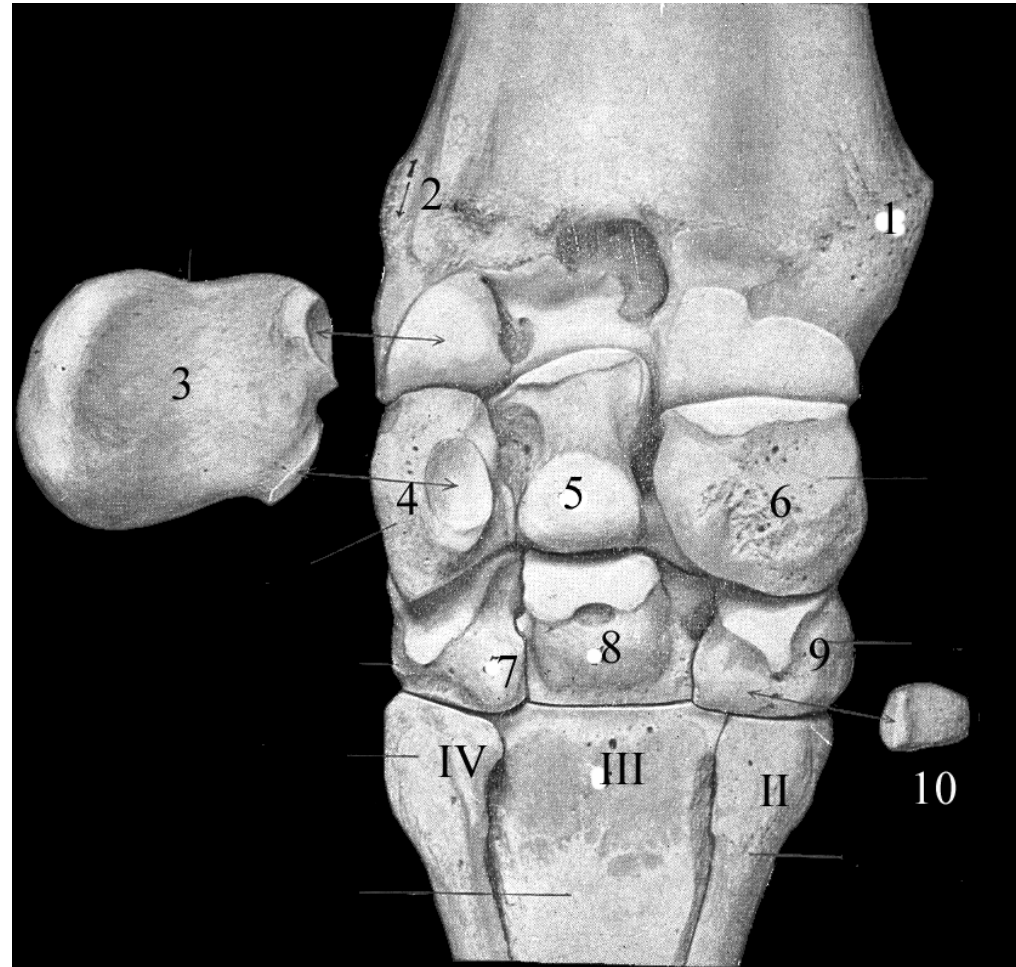
Ver referencias en imagen

2. Vista medial



Huesos del carpo

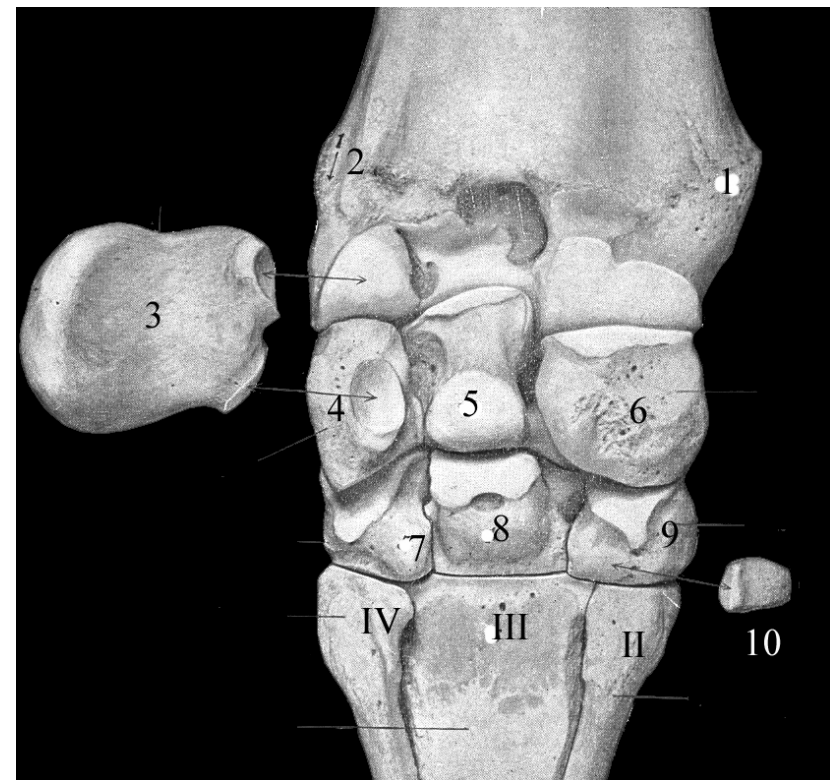
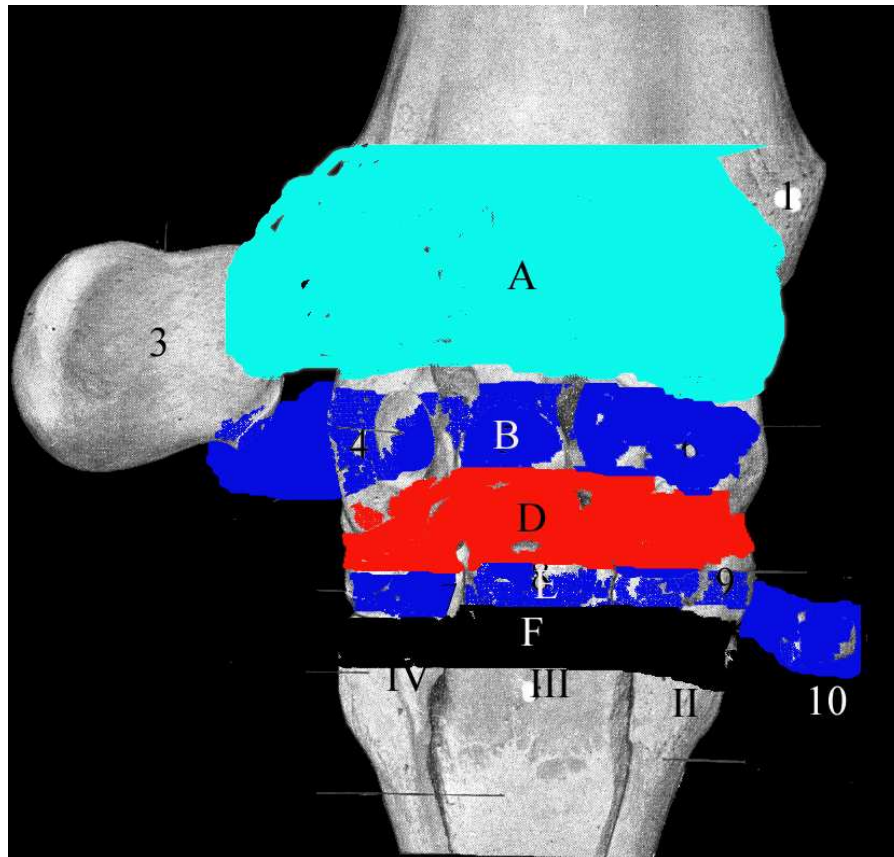
Ver referencias en imagen
2. Vista palmar.



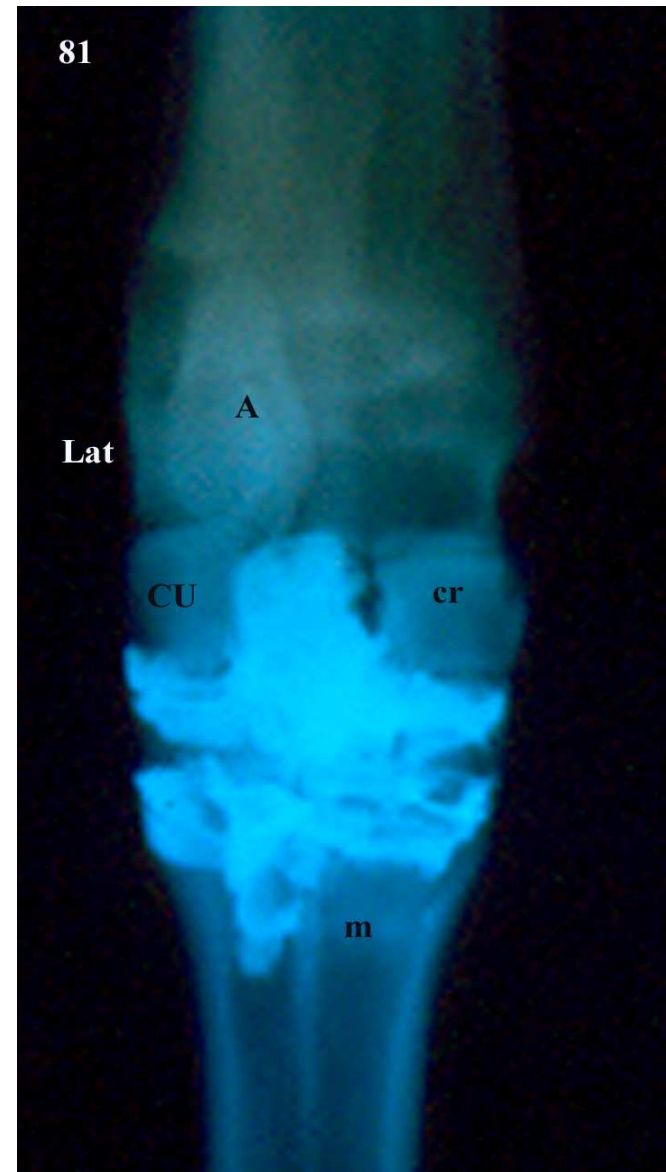
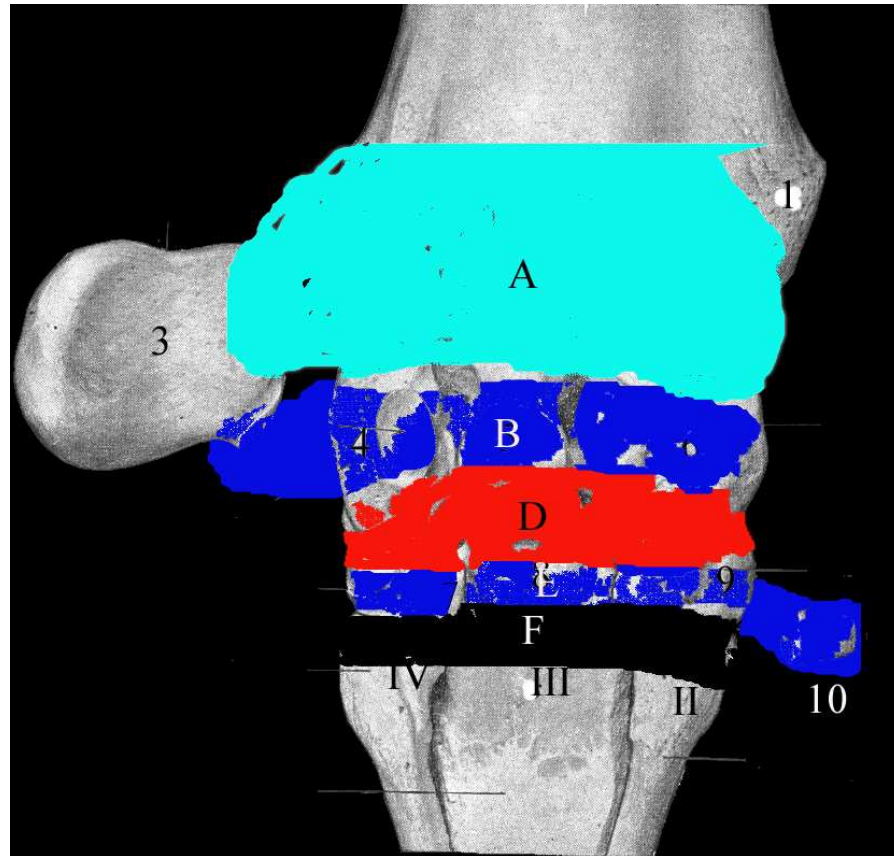
Articulaciones del carpo

Sacos articulares

A antebraquiocarpiana, D medio carpiana, B intercarpiana proximal, E int distal, F carpometacarpiana,

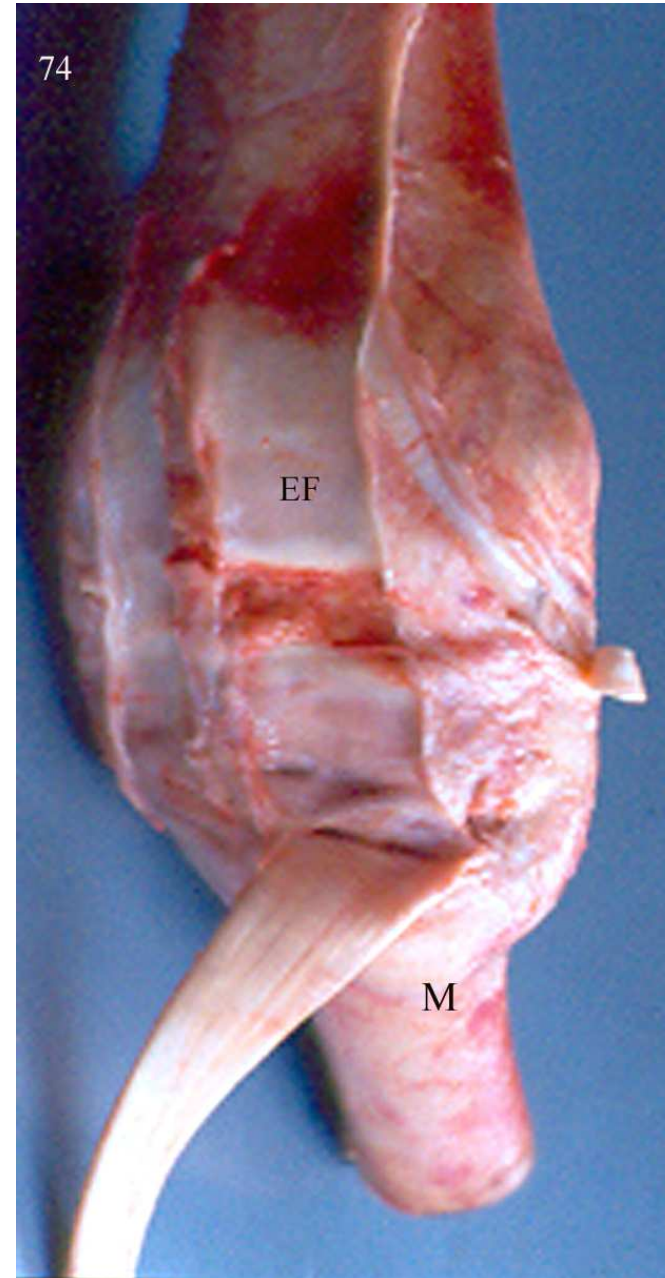


Sacos articulares



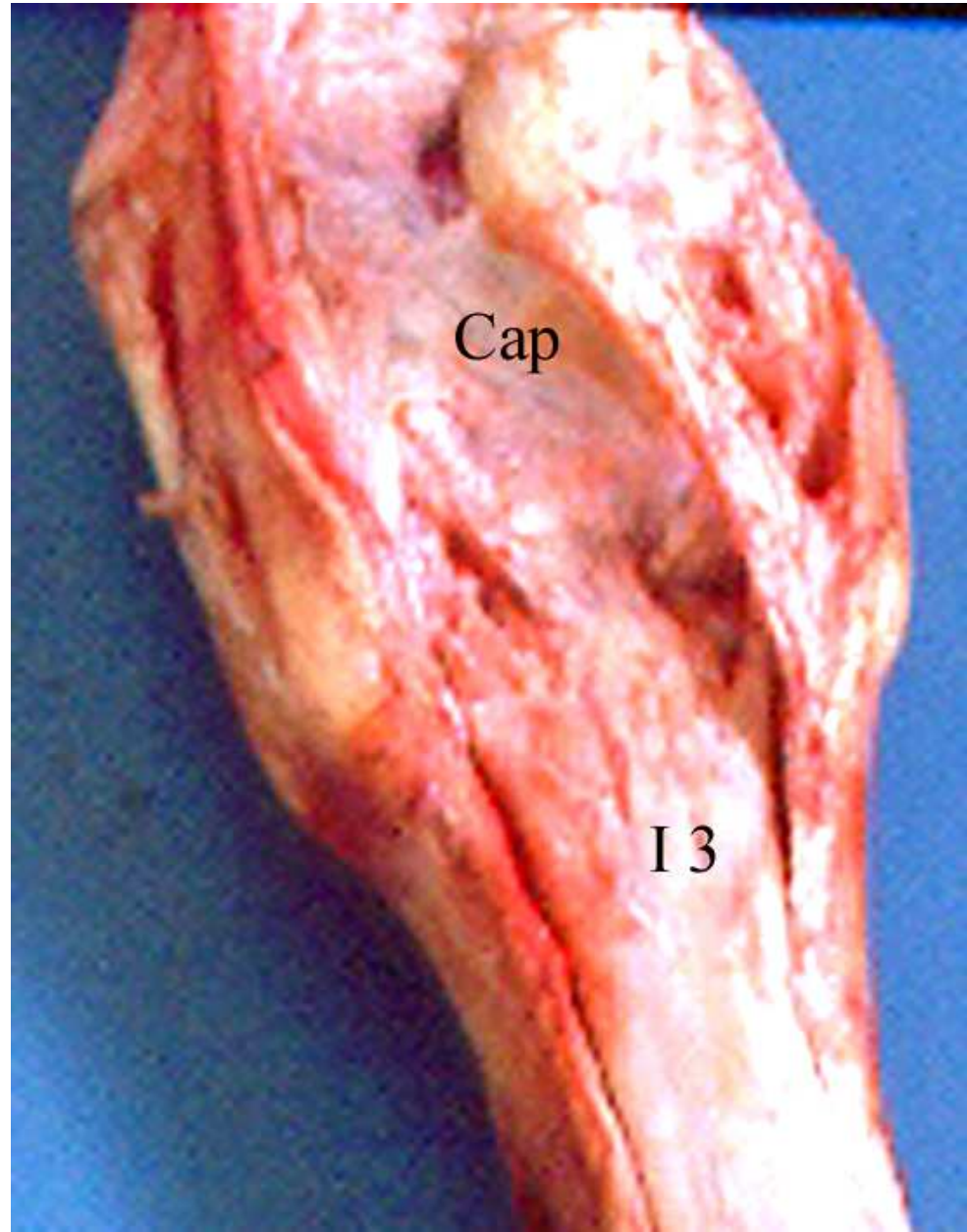
Cara dorsal carpo

- EF, estrato fibroso común:
membrana dorsal
- M, tuberosidad del extensor
carporradial



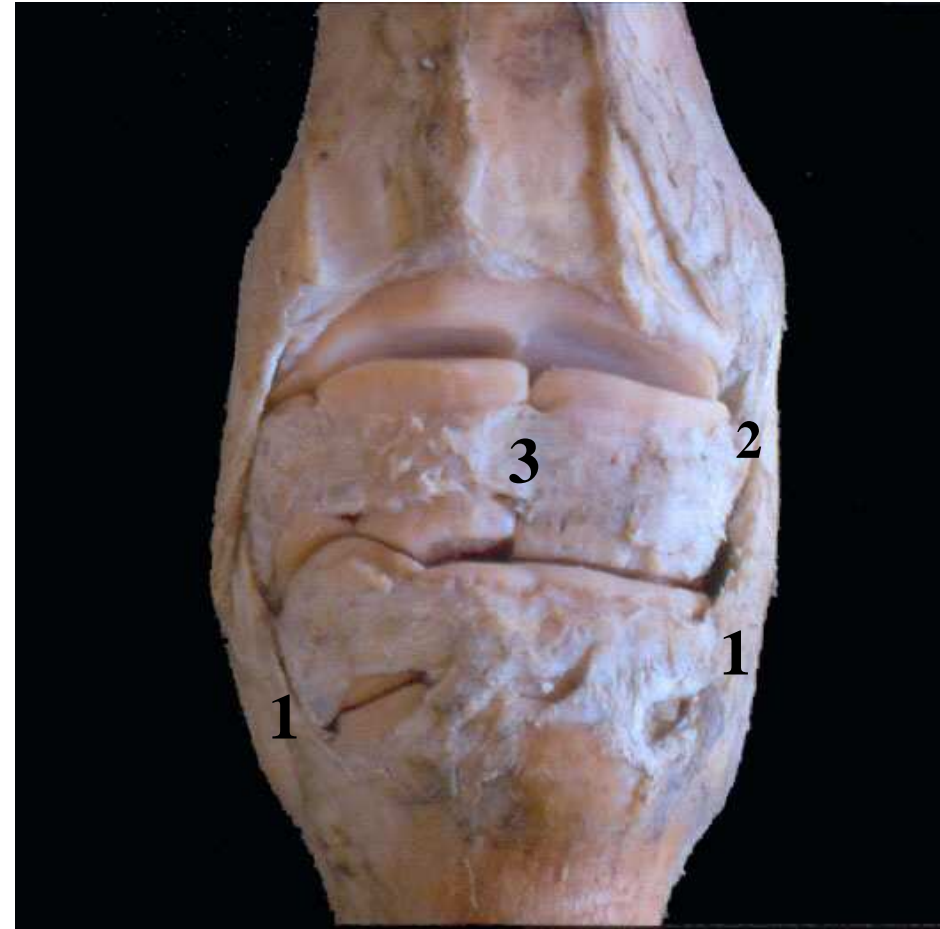Cara palmar del carpo

- Cap: estrato fibroso: ligamento palmar.
- I 3: m. inteóseo III



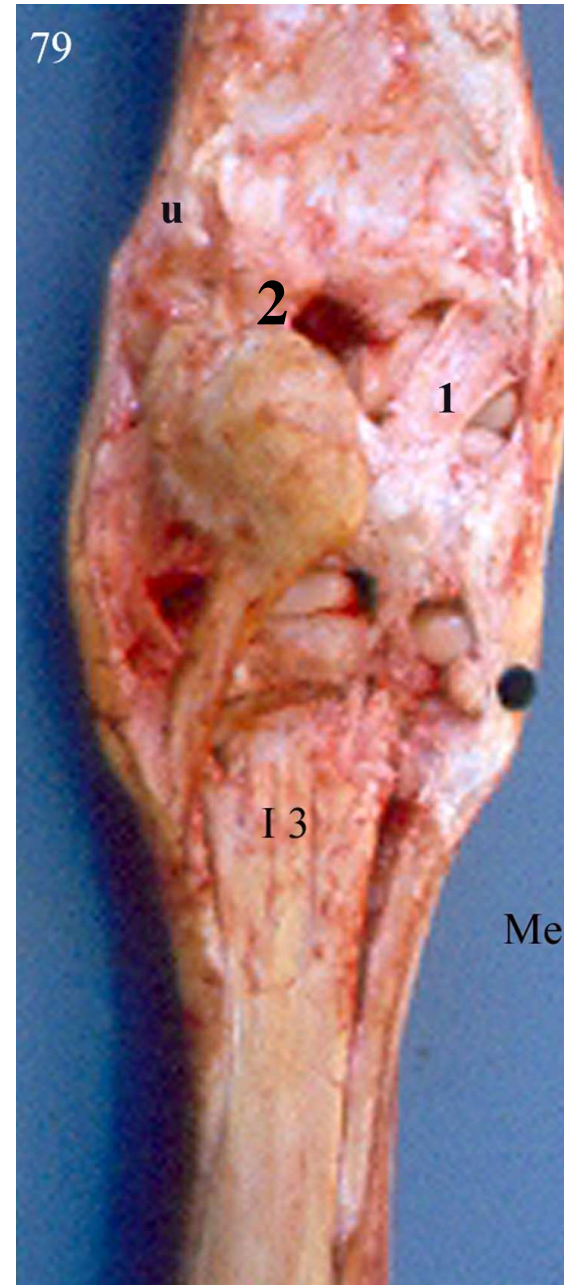
Medios de unión

- 1, ligtos colaterales
- 2, porción profunda
- 3, lgtos dorsales



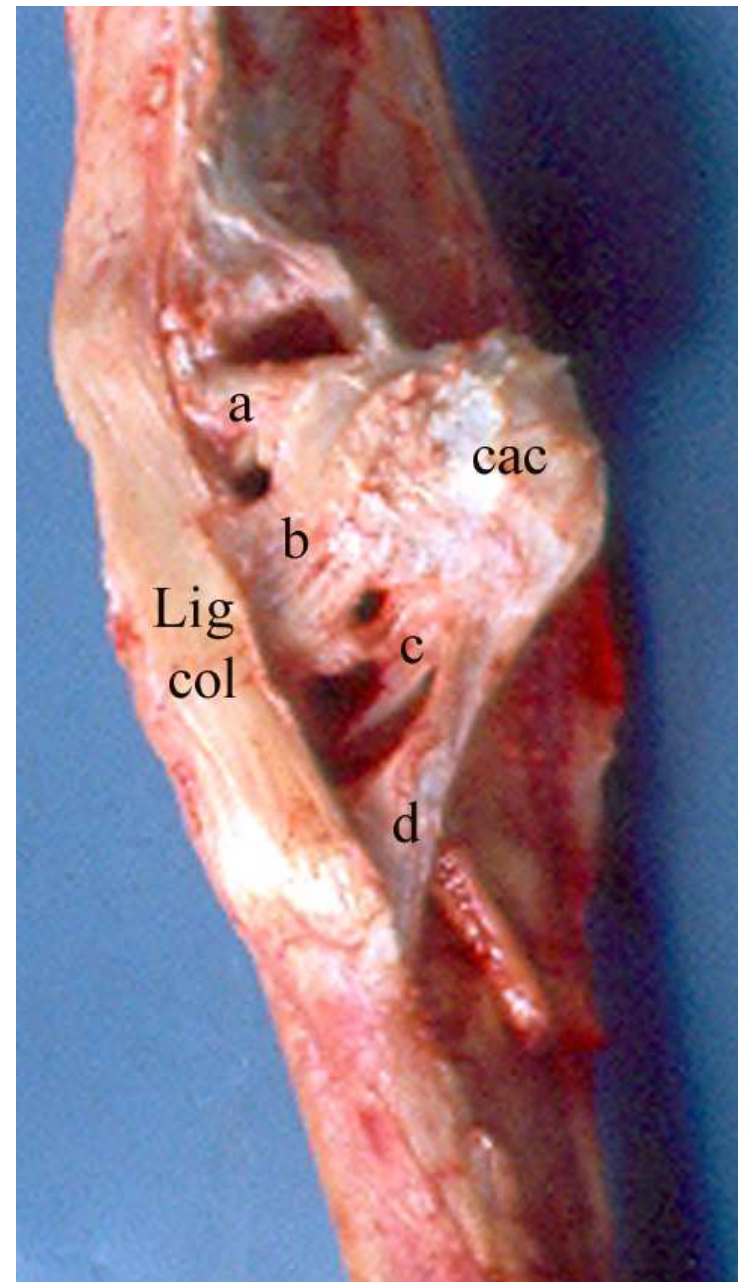
Palmar del carpo

- 1, ligto radio carpiano palmar
- 2, ligto ulnocarpiano palmar
- Marcador negro, I hueso
- I 3, interóseo III



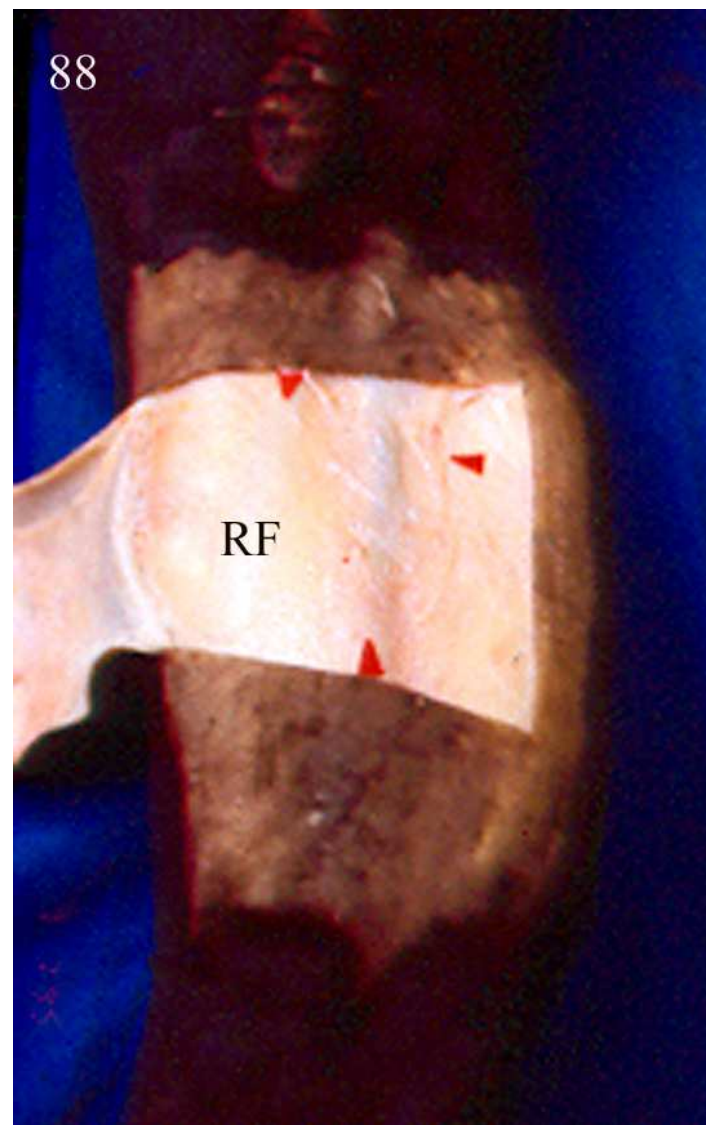
Art. del hueso accessorio

- a ligto
accessorio-
ulnar.
- b ligto
accessorio
carpoulnar
- c ligto
accessorio-
IVcarpal
- d accesorio
metacarpal



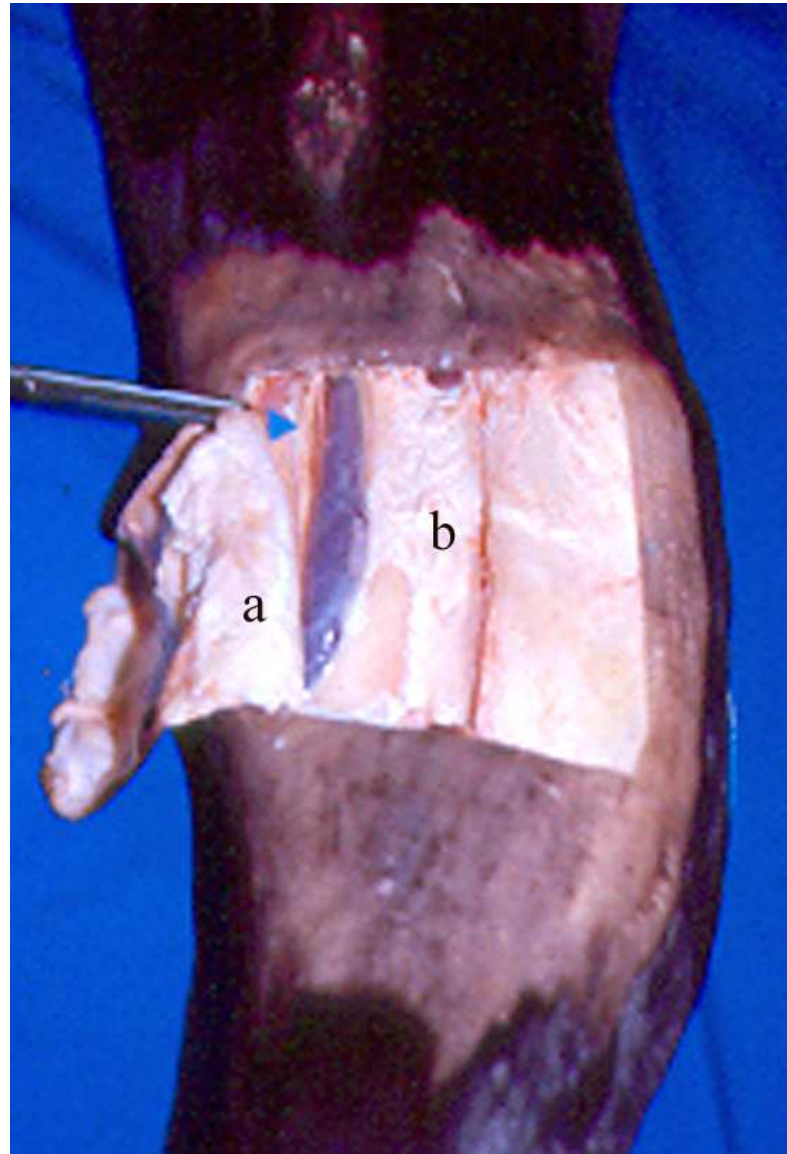
Retináculo flexor

- **RF** hoja superficial



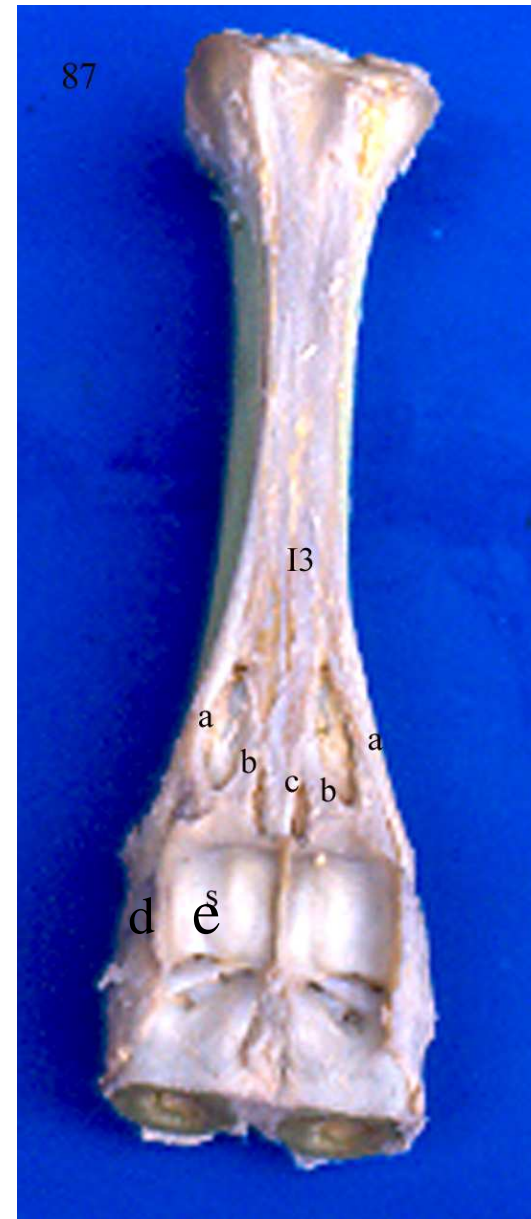
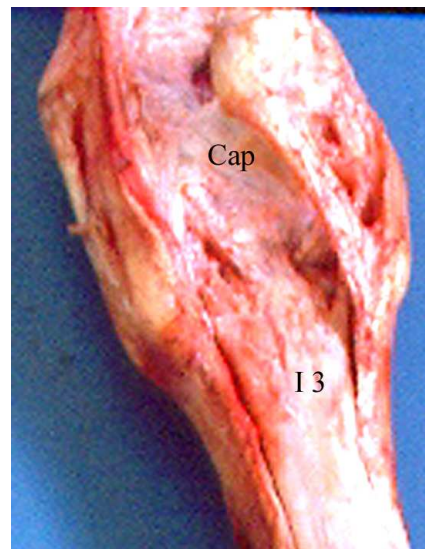
Retináculo flexor

- a hoja superficial
- b hoja profunda



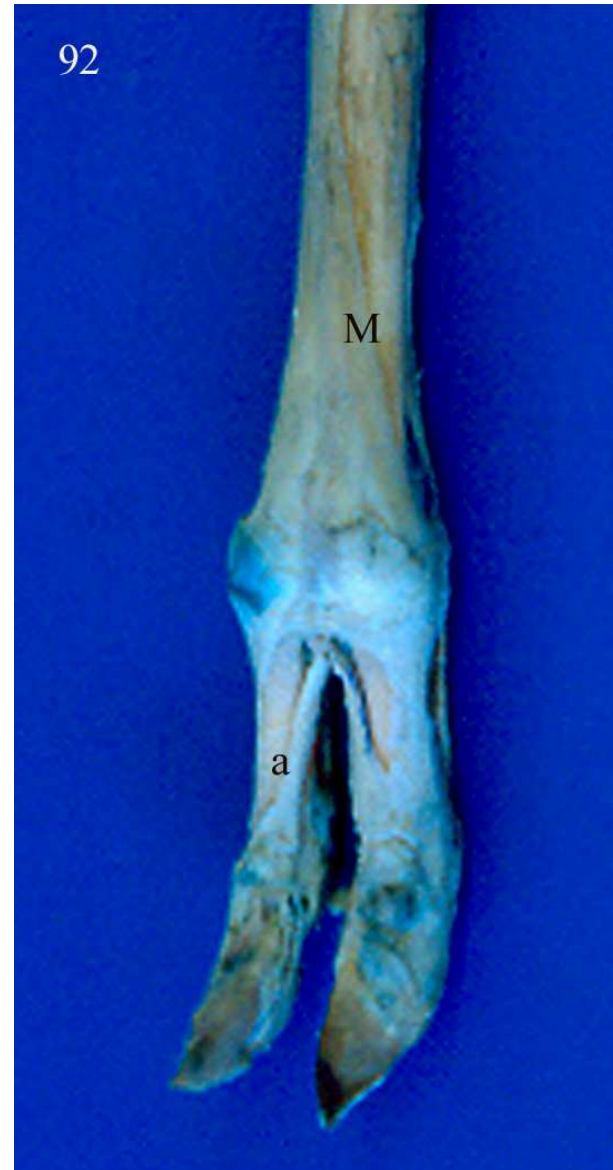
Interóseo III

- i 3 interóseo iii
- a rama abaxial
- c rama axial
- d ligto intersesamoideo interdigital
- e lgto intersesamoideo

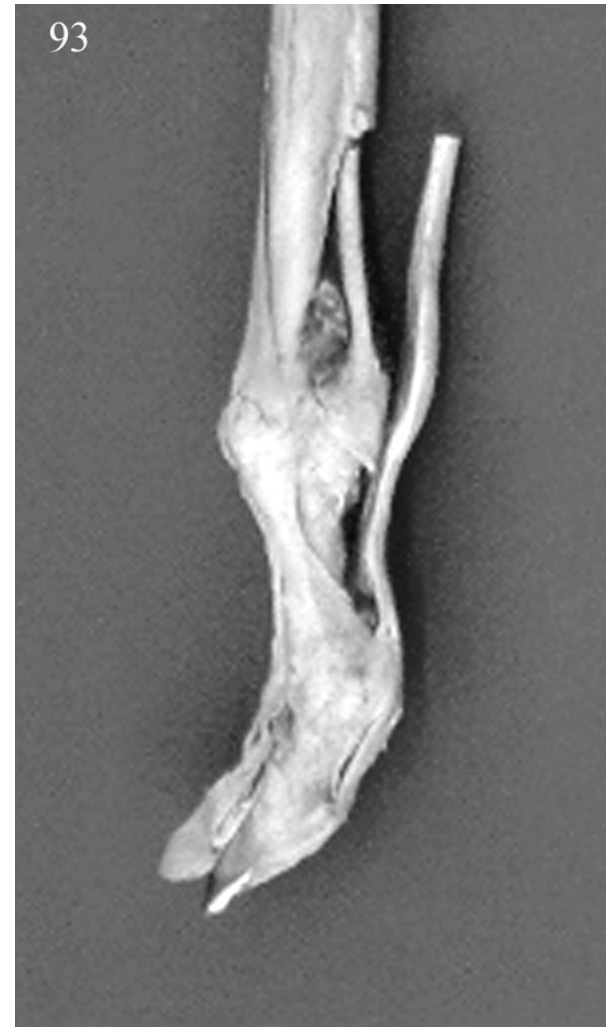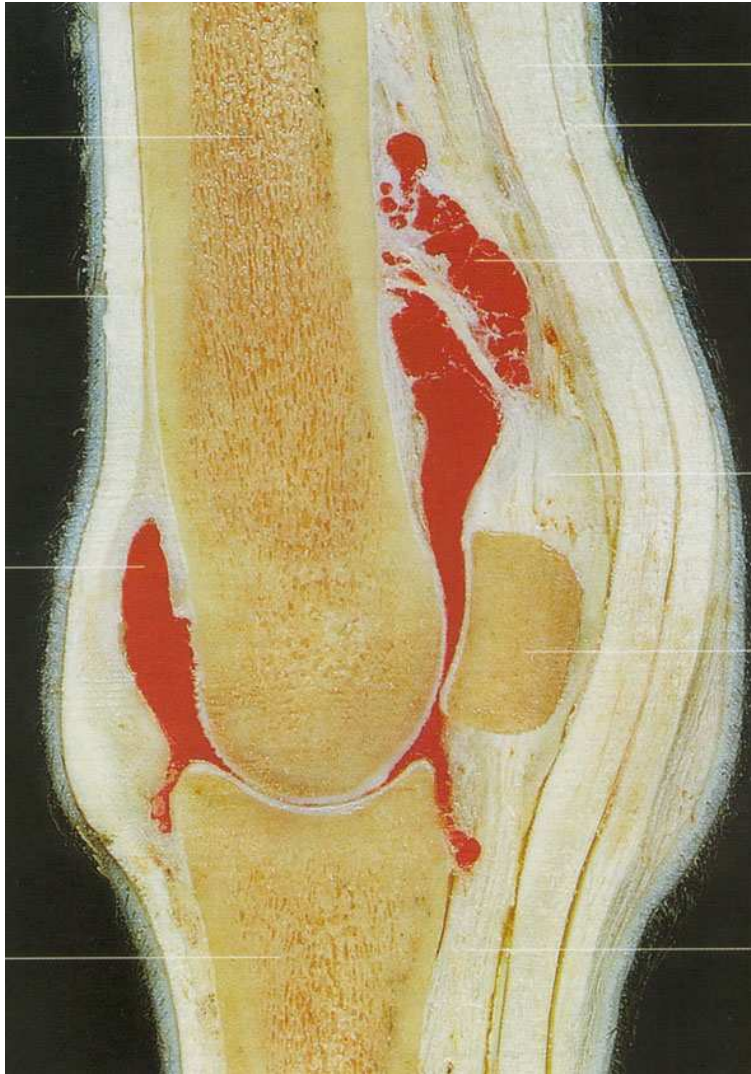


Interóseo III

- a ramas axiales

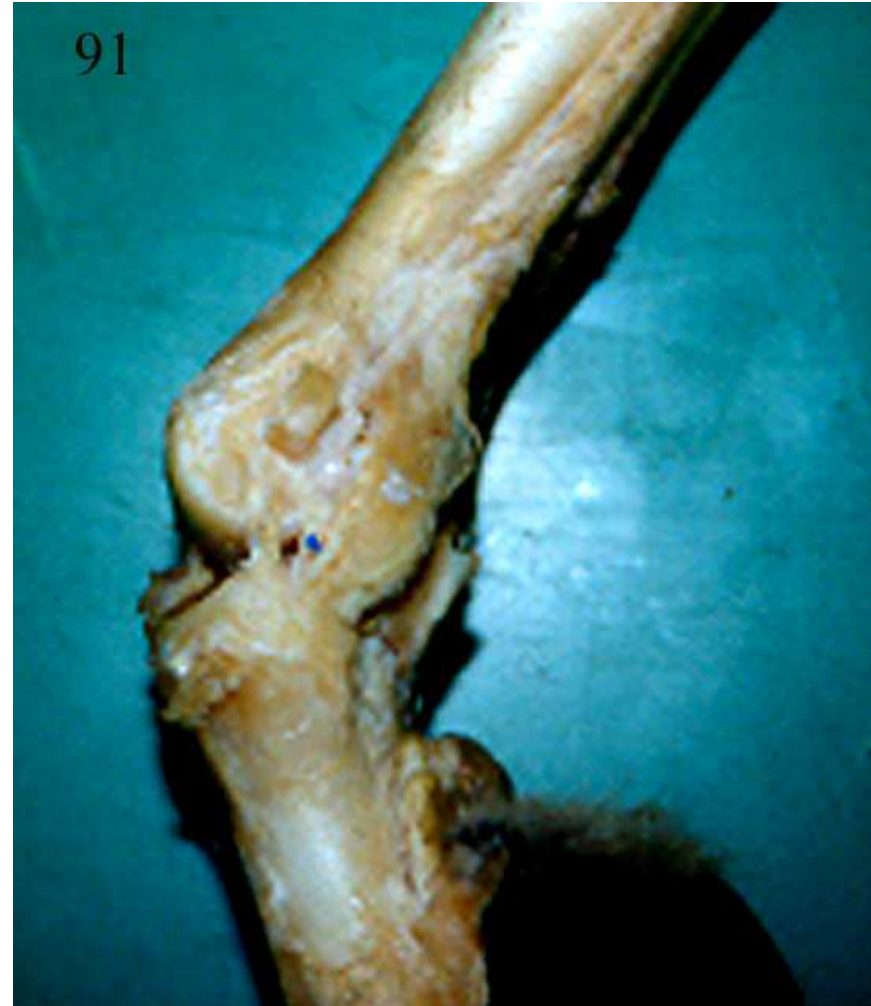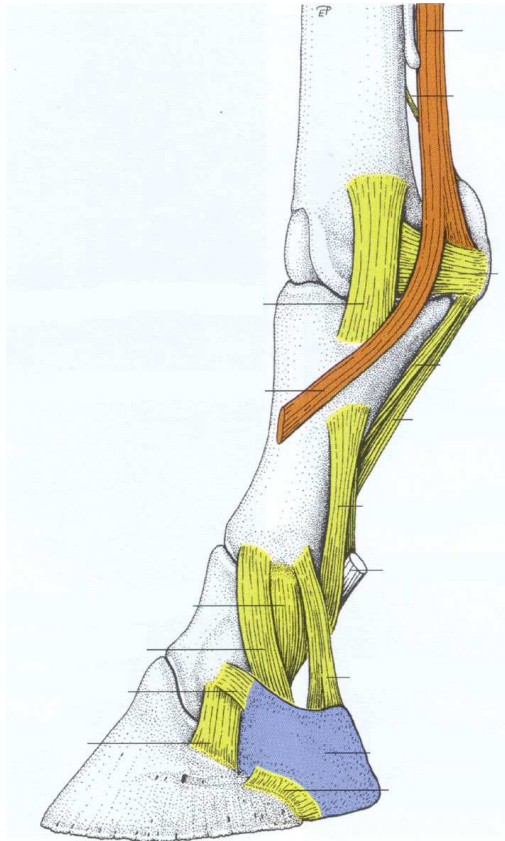


Recesos sinoviales



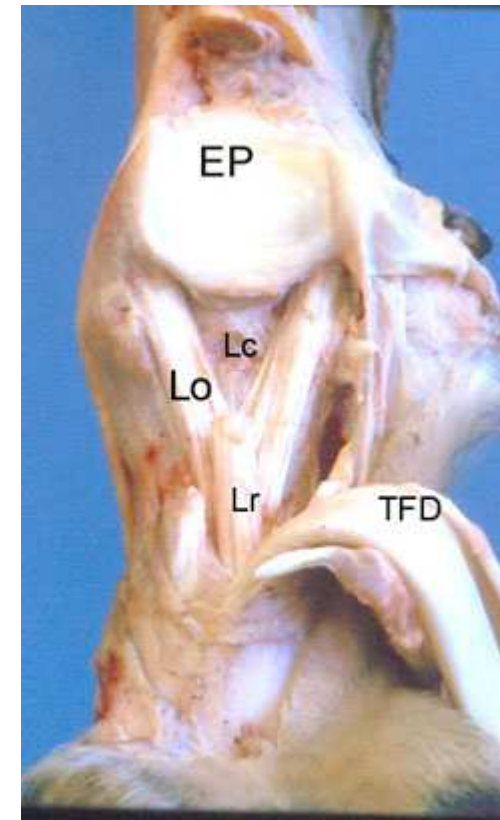
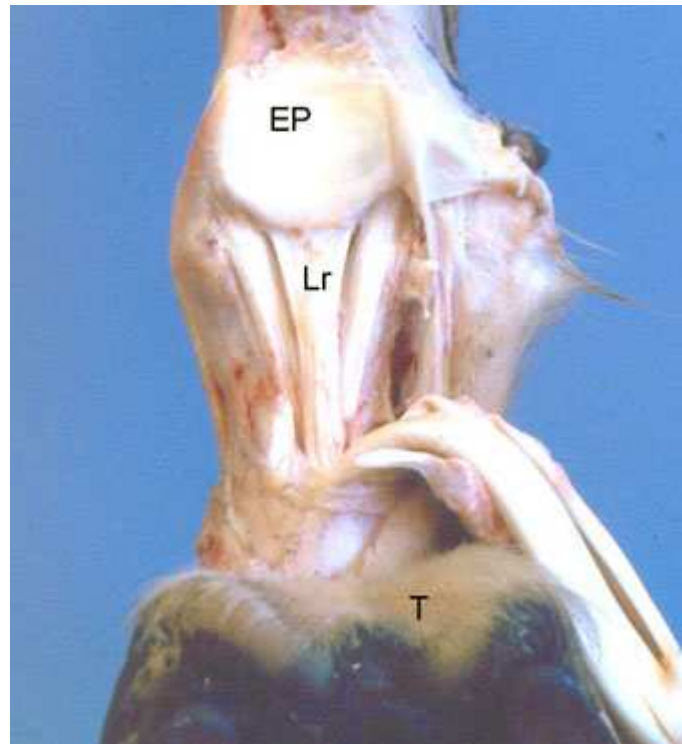
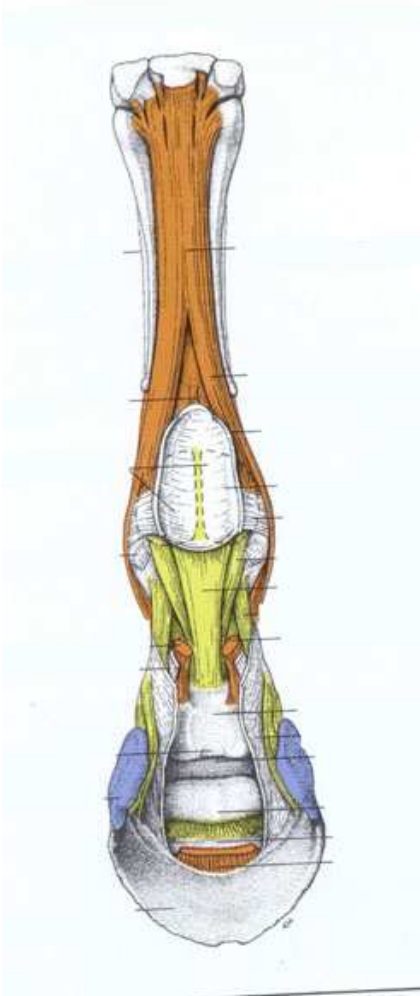
Artic metacarpofalángica

- Ligamentos colaterales



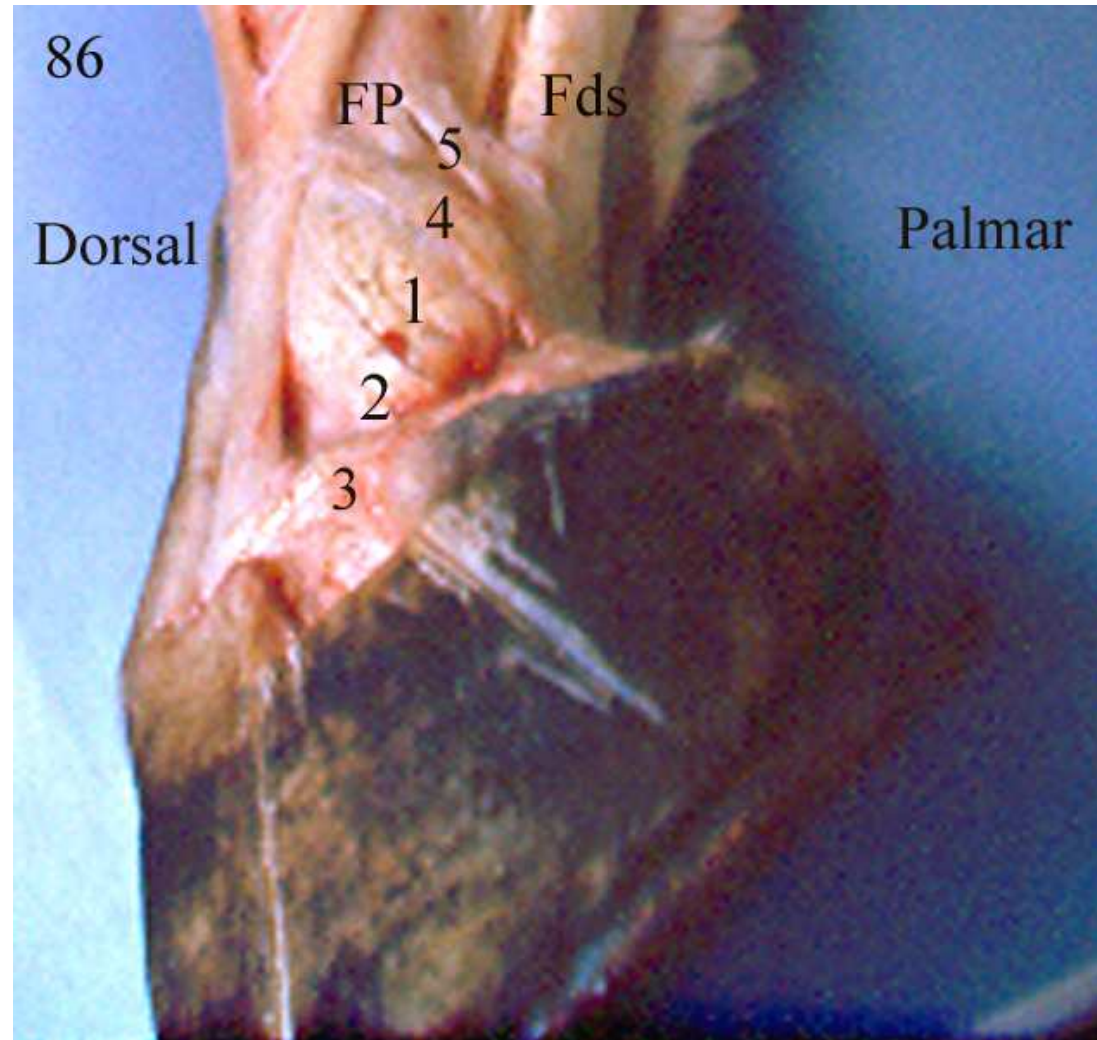
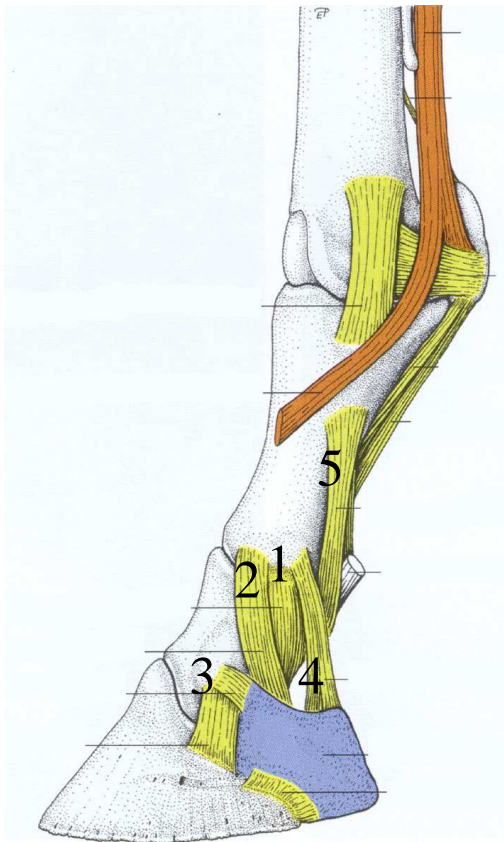
Lgts sesamoideos distales

- EP lgto intersesamoideo, Lo ligamentos oblicuos, Lr ligto recto, Lc lgts cruzados TFD tendón flexor digital profundo



Lgto interfalanganos

- 1lgto colateral FP-FM, 2 lgto sesamoideo colateral ,3 lgto condrocoronario, 4 lgto condrocompedal



Artic del dedo

- 1 tendón FDP, 2 falange proximal, 3 falange media, 4 falange distal, 5 sesamoideo distal.
- El marcador verde indica el espacio ocupado por la bolsa podotrocLEAR, 6 víncula tendínea

